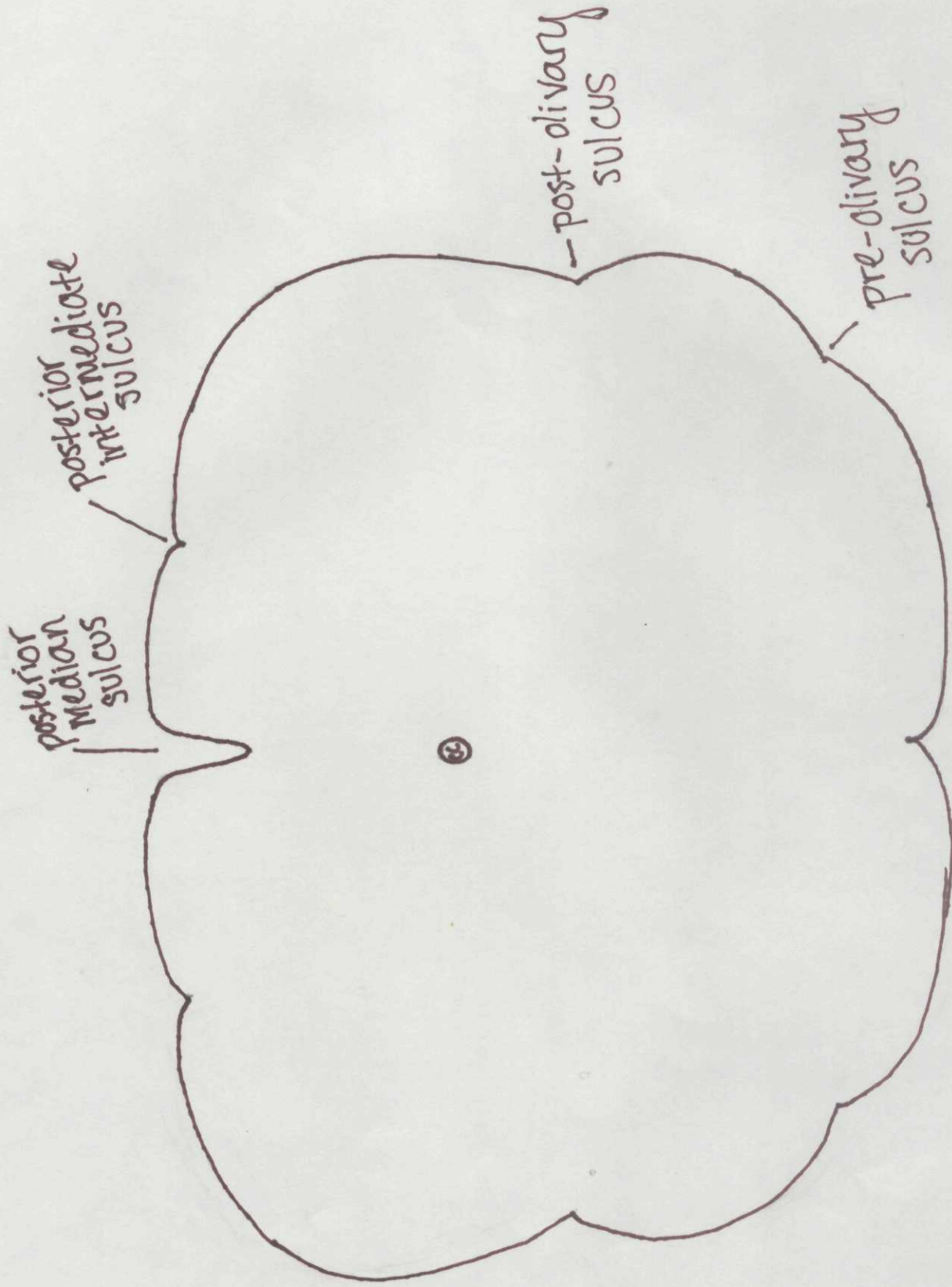


# Lower Medulla



# Lower Medulla

CNN

Spinal tract of V

Spinal nucleus of V

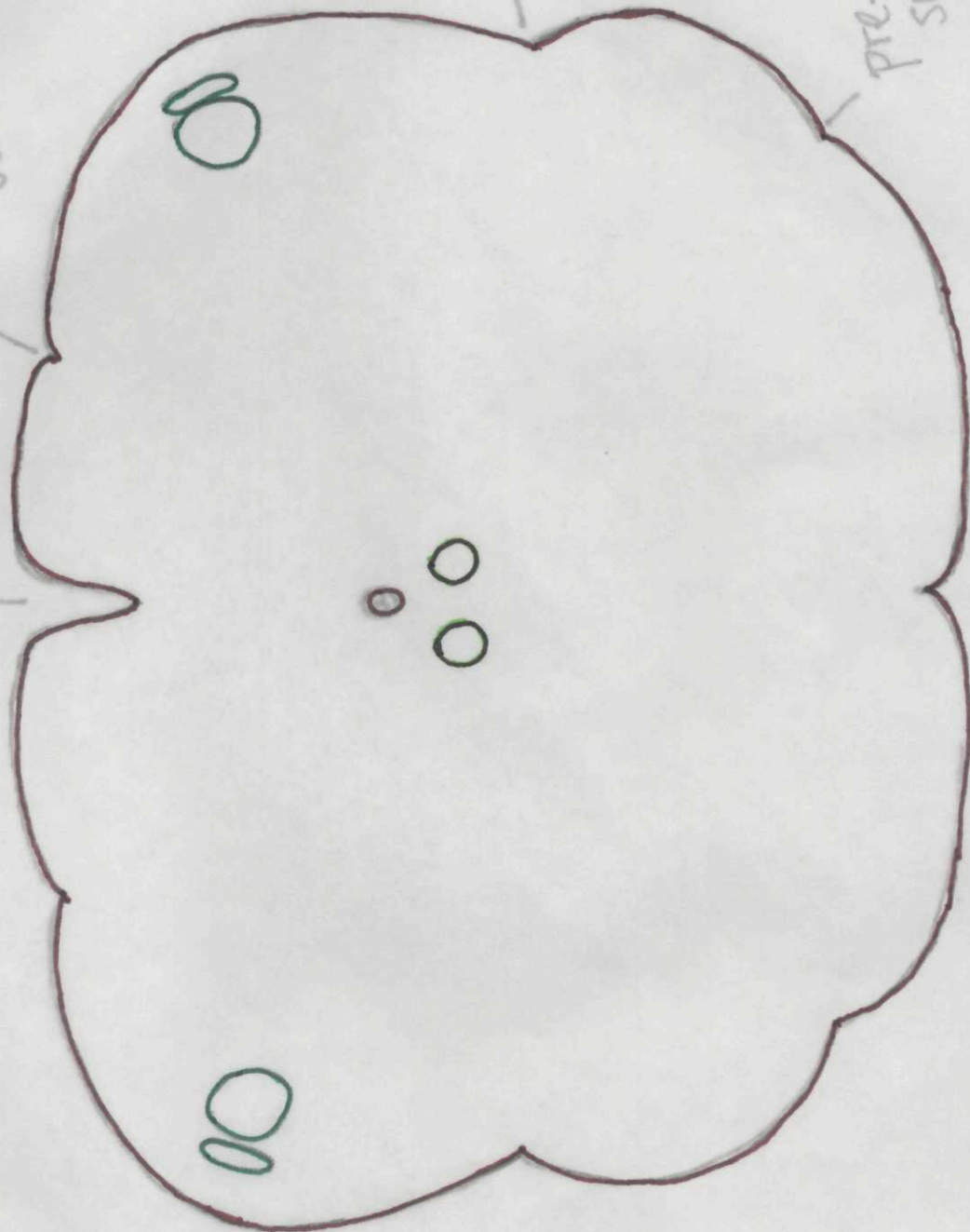
MLF

posterior median sulcus

posterior intermediate sulcus

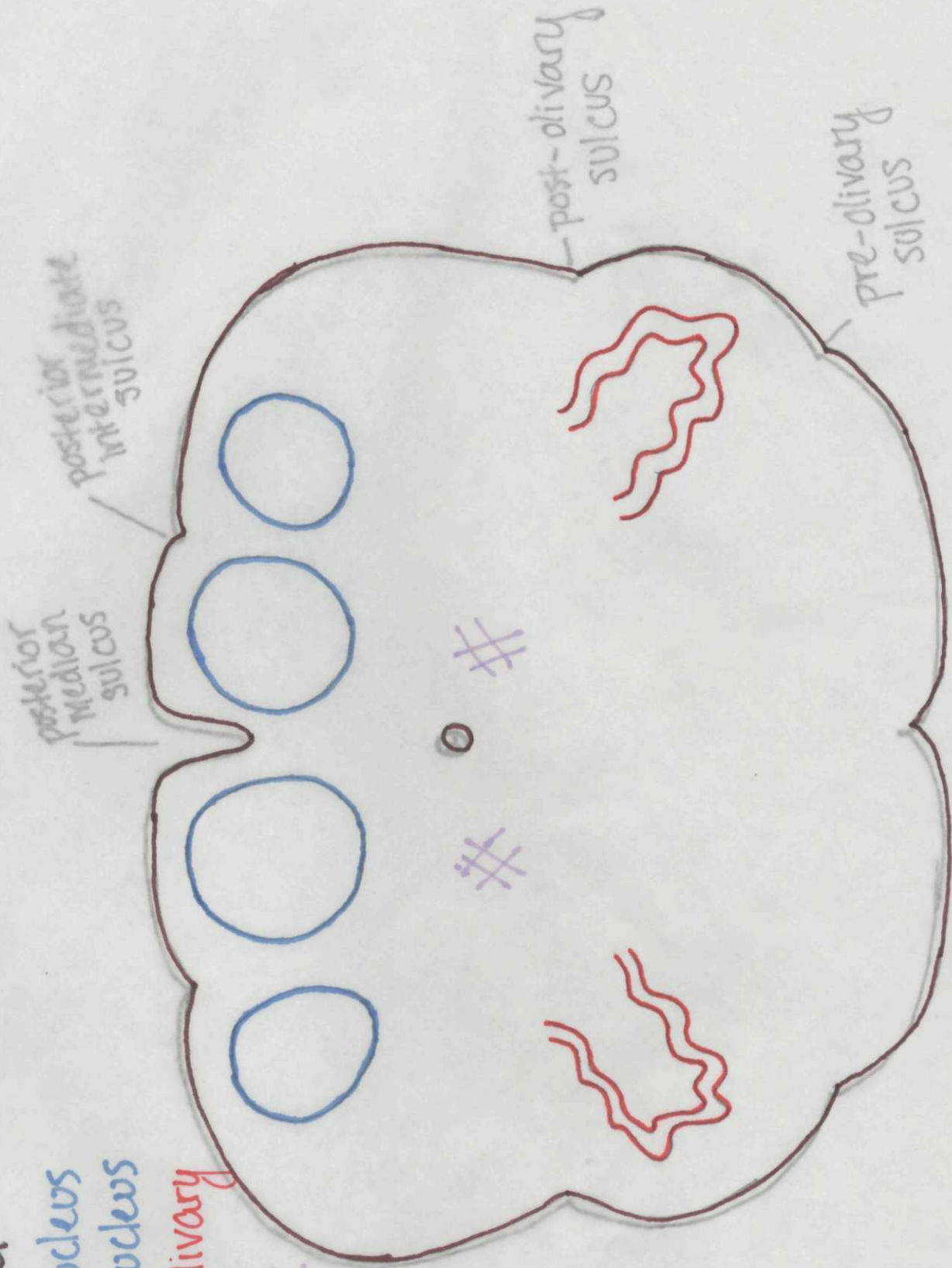
post-olivary sulcus

pre-olivary sulcus



# Lower Medulla

- Other Nuclei
- Gracile Nucleus
- Cuneate Nucleus
- Inferior Olivary Nucleus
- Reticular F.





# Lower Medulla

White Matter Tracts

Gracile F.

Cuneate F.

Medial Lemniscus

Internal

Arcuate F.

Central

Tegmental T.

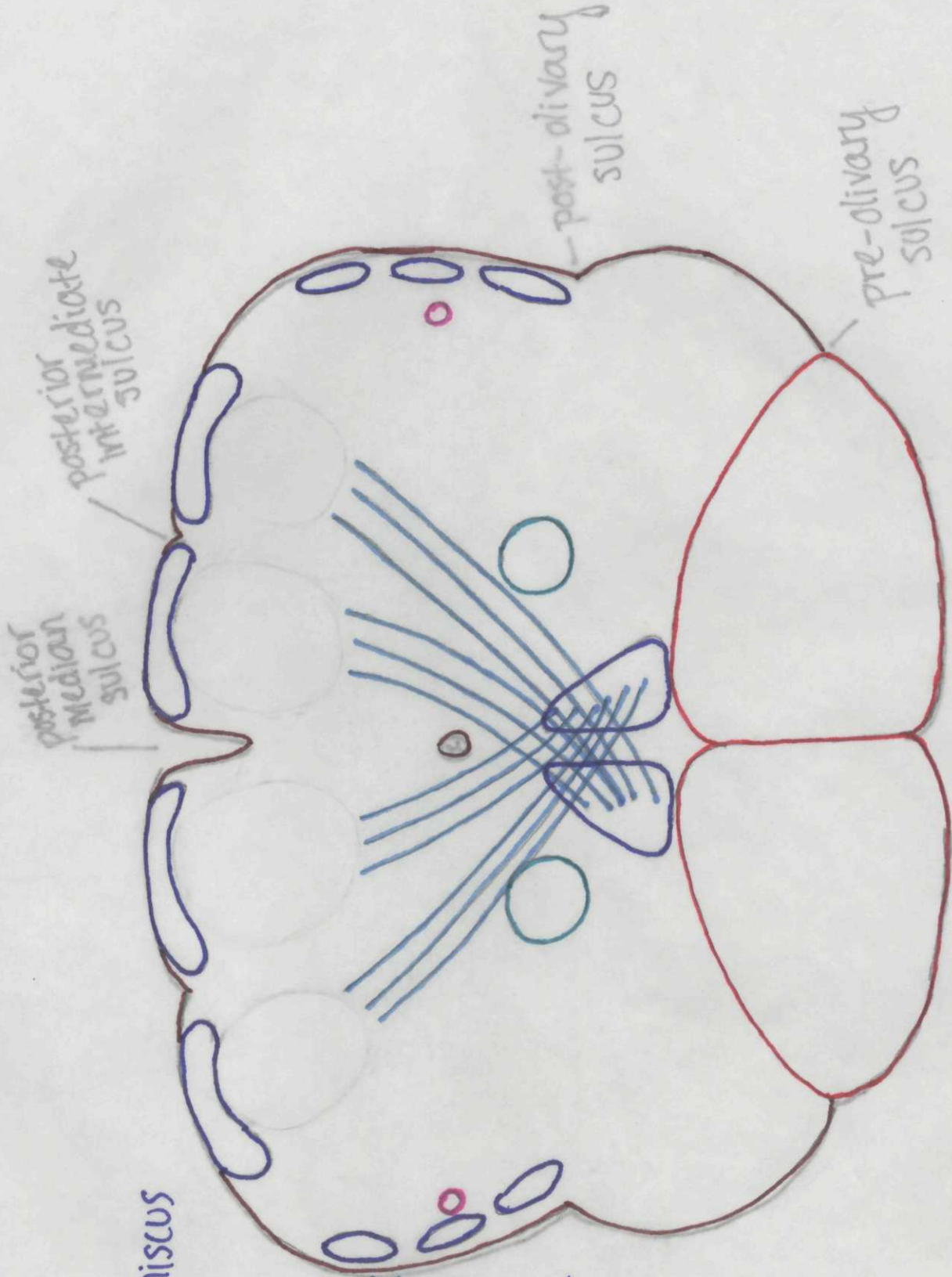
Post Spinocereb.

Ant Spinocereb.

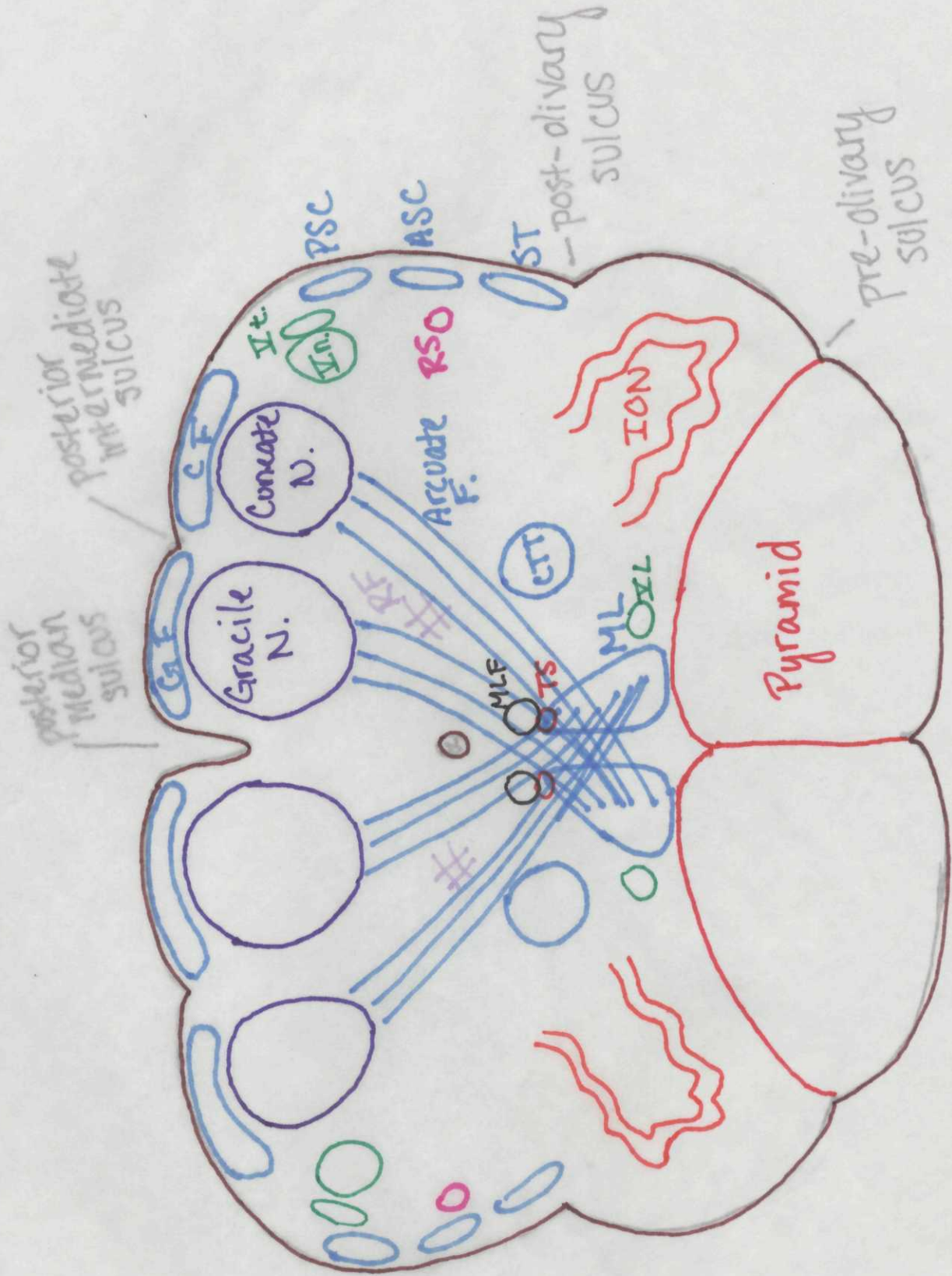
Spinothalamic  
(ALS)

Rubrospinal

Pyramids



# Lower Medulla





# Lower Medulla

