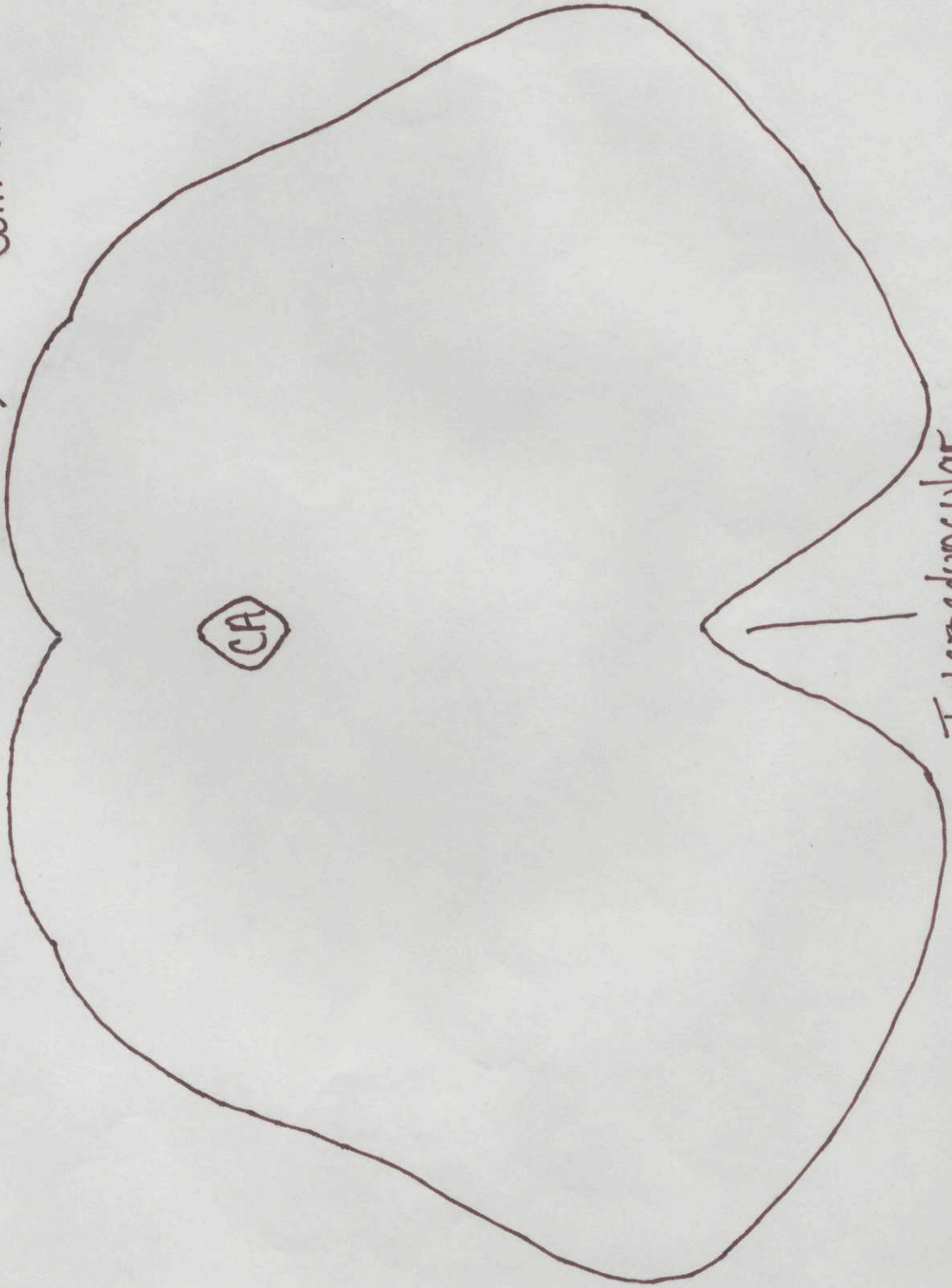


Lower Midbrain

Inferior Colliculus

CA

Interpeduncular Fossa



CNN

MLF

Trochlear

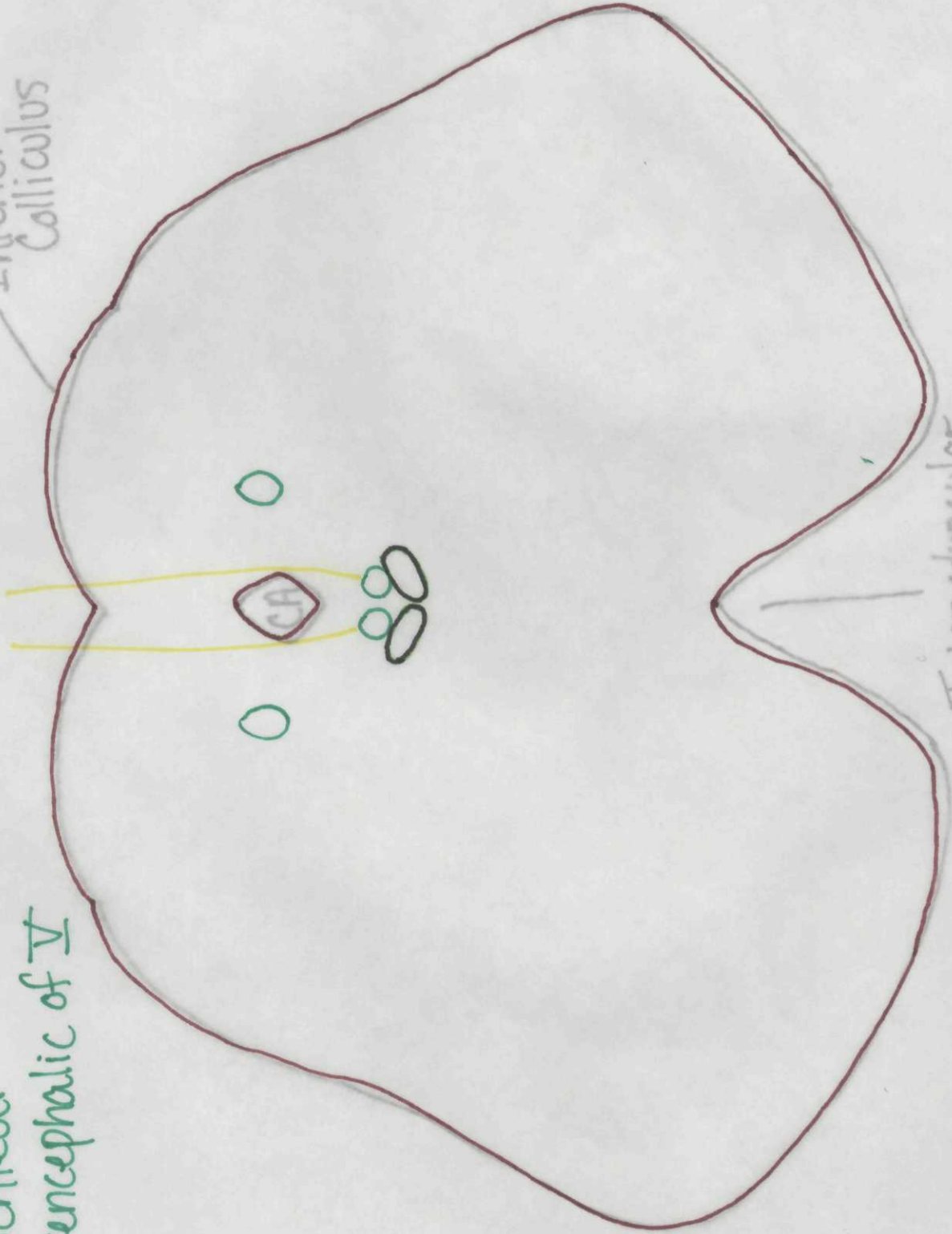
Mesencephalic of V

Lower

Midbrain

Inferior  
Colliculus

Interpeduncular  
Fossa



Lower Midbrain

Other Nuclei

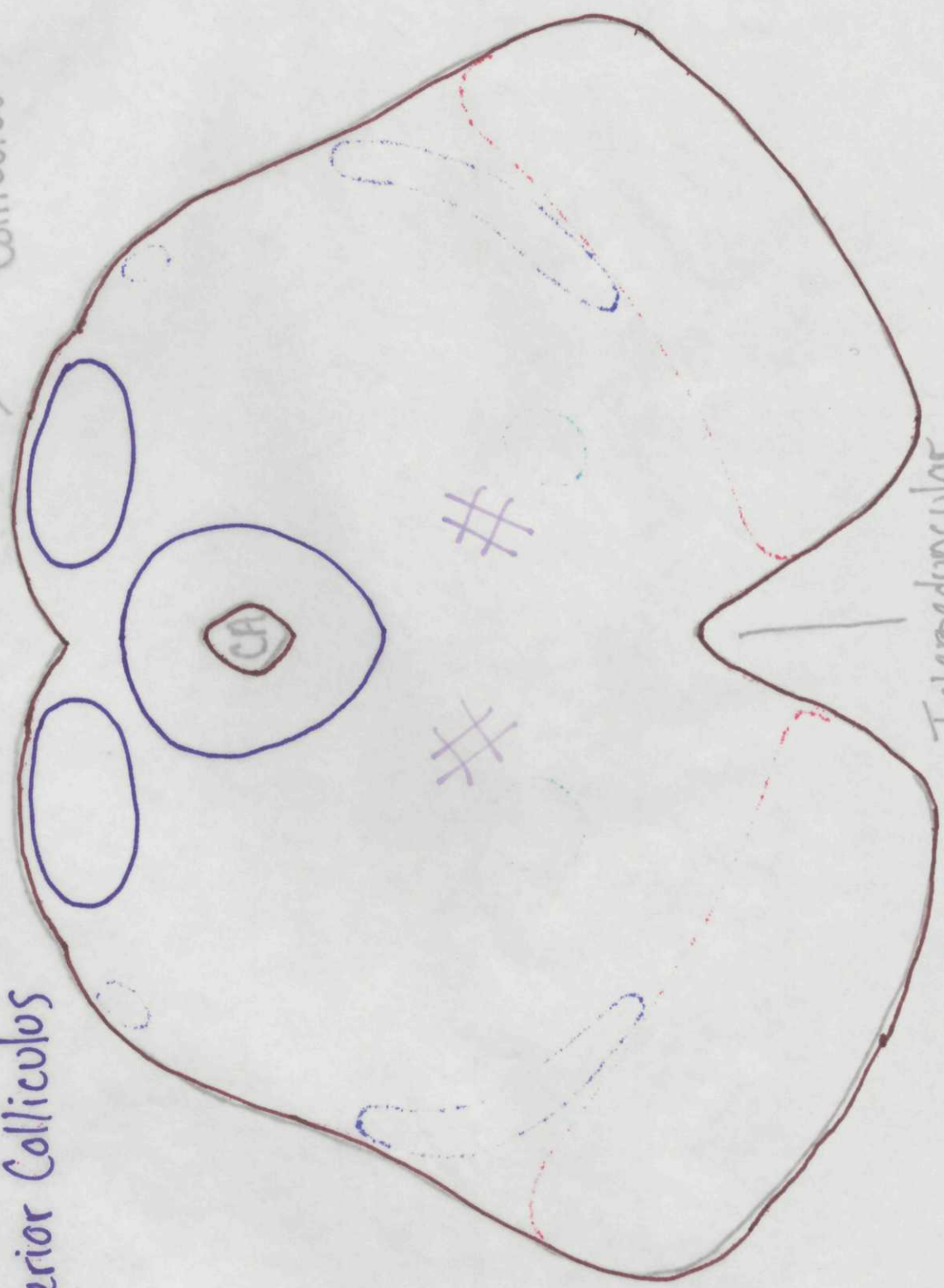
Periaqueductal Gray

Reticular F.

Inferior Colliculus

Inferior Colliculus

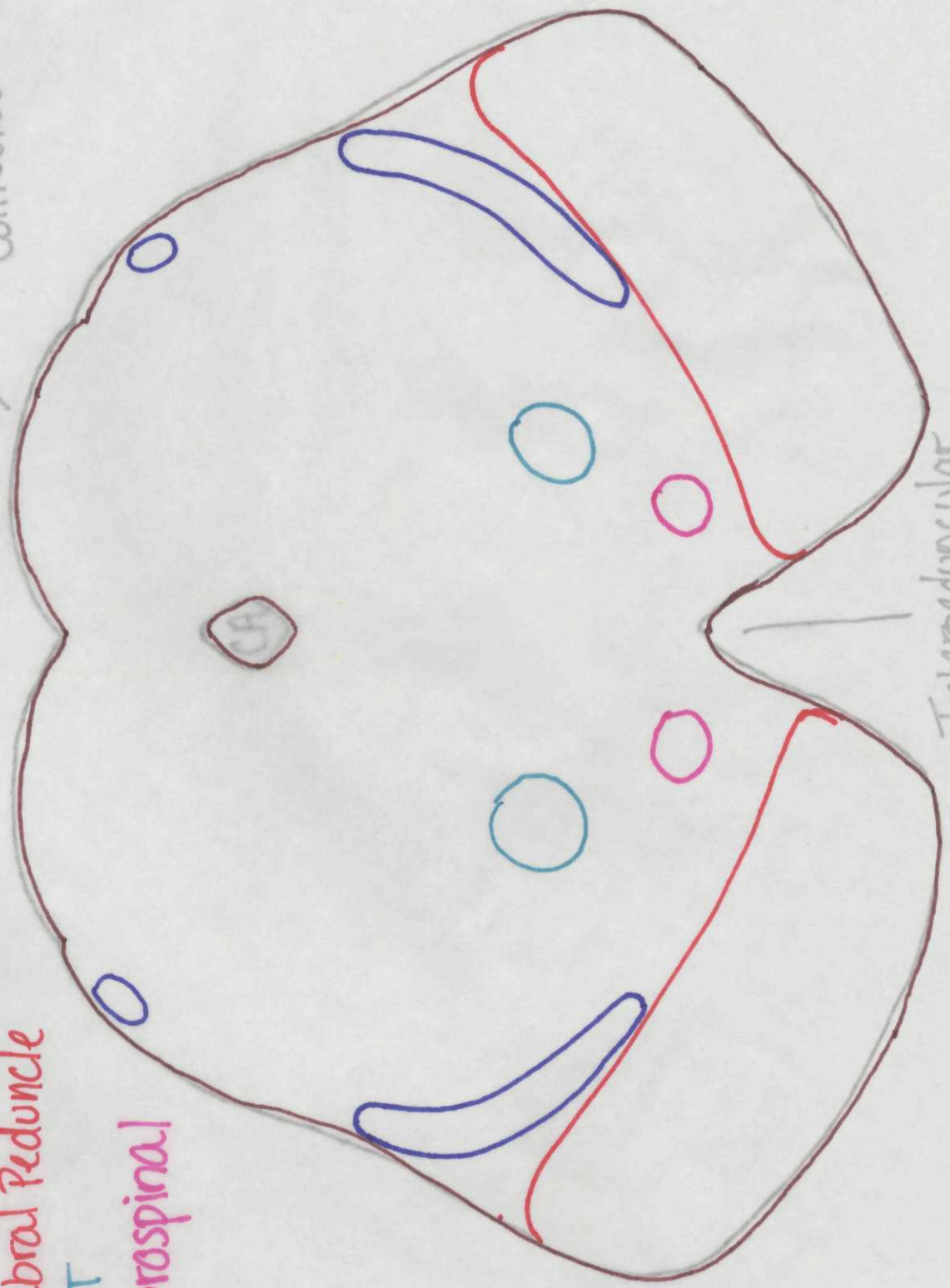
Interpeduncular Fossa



White Matter Tracts  
Lower Midbrain

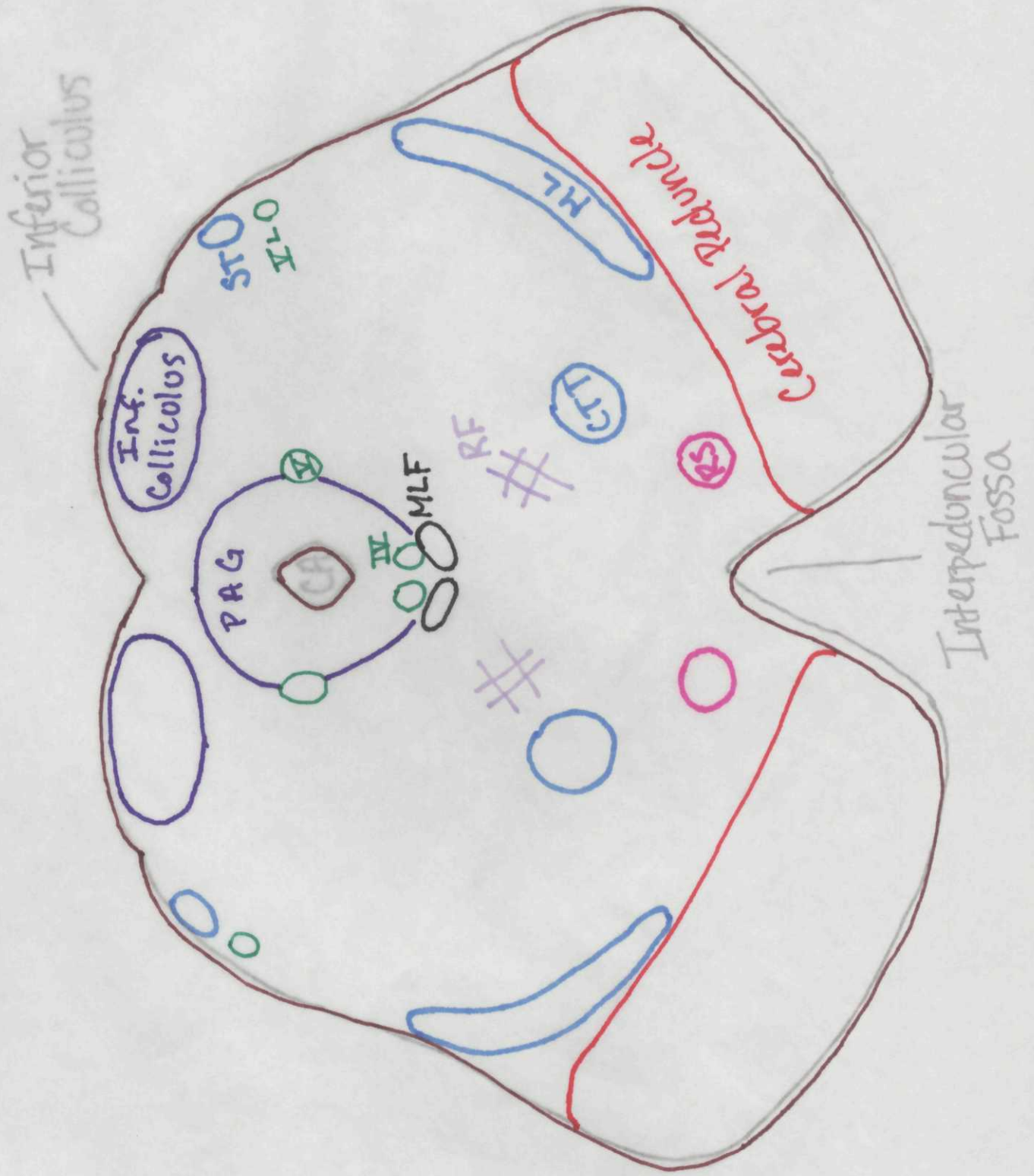
Medial Lemniscus  
Spinothalamic T.  
Cerebral Peduncle  
CTT  
Rubrospinal

Inferior Colliculus



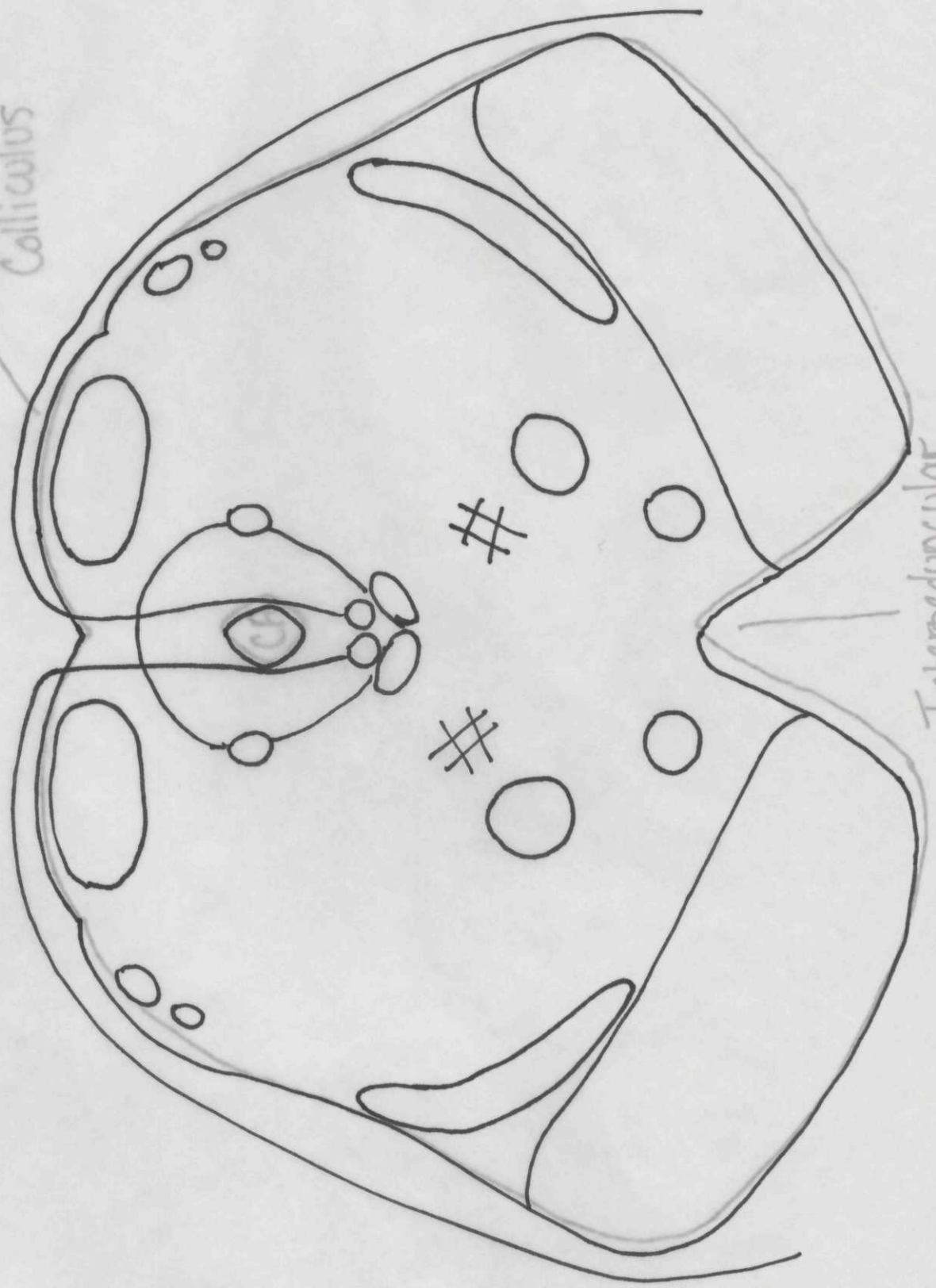
Interpeduncular Fossa

# Lower Midbrain



Lower Midbrain

Inferior Colliculus



Interpeduncular Fossa