

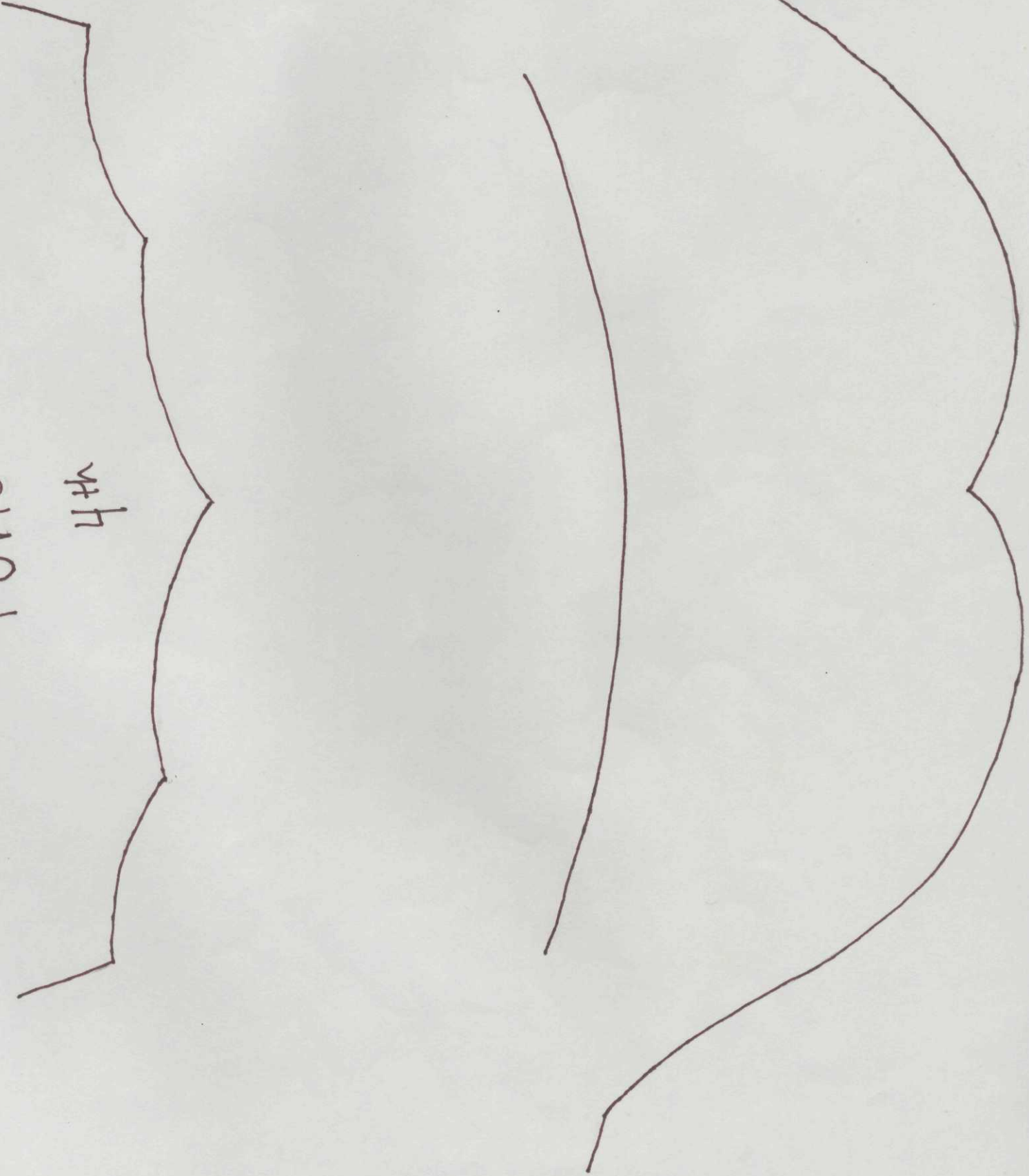
PONS

4th

Superior
Cerebellar
Peduncle

Middle
Cerebellar
Peduncle

Basis
Pontis



PONS

4th

CNN

Spinal Nucleus of V

MLF

Vestibul.

Cochlear

Motor Nucleus of V

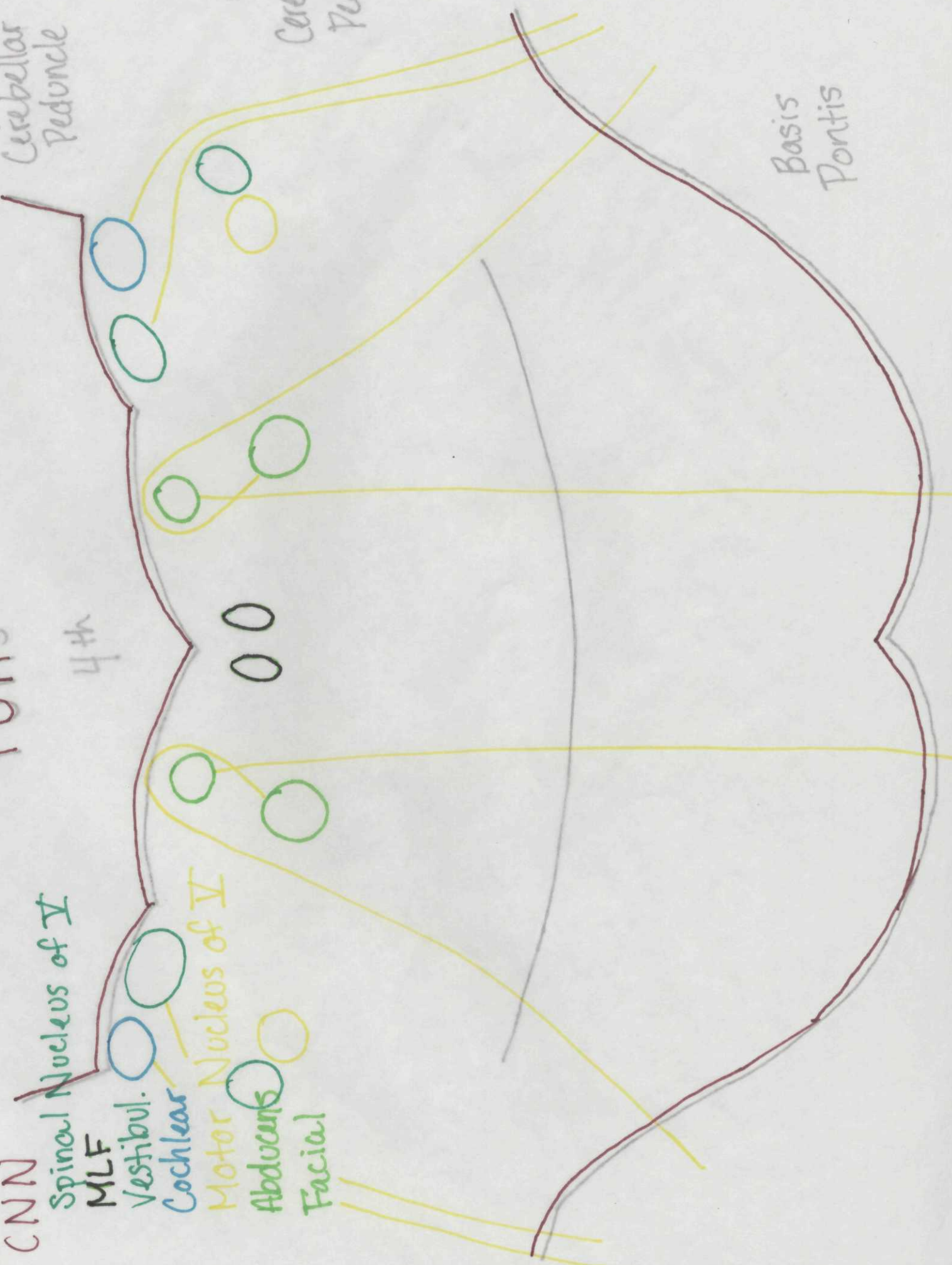Abducens

Facial

Superior
Cerebellar
Peduncle

Middle
Cerebellar
Peduncle

Basis
Pontis



PONS

4th

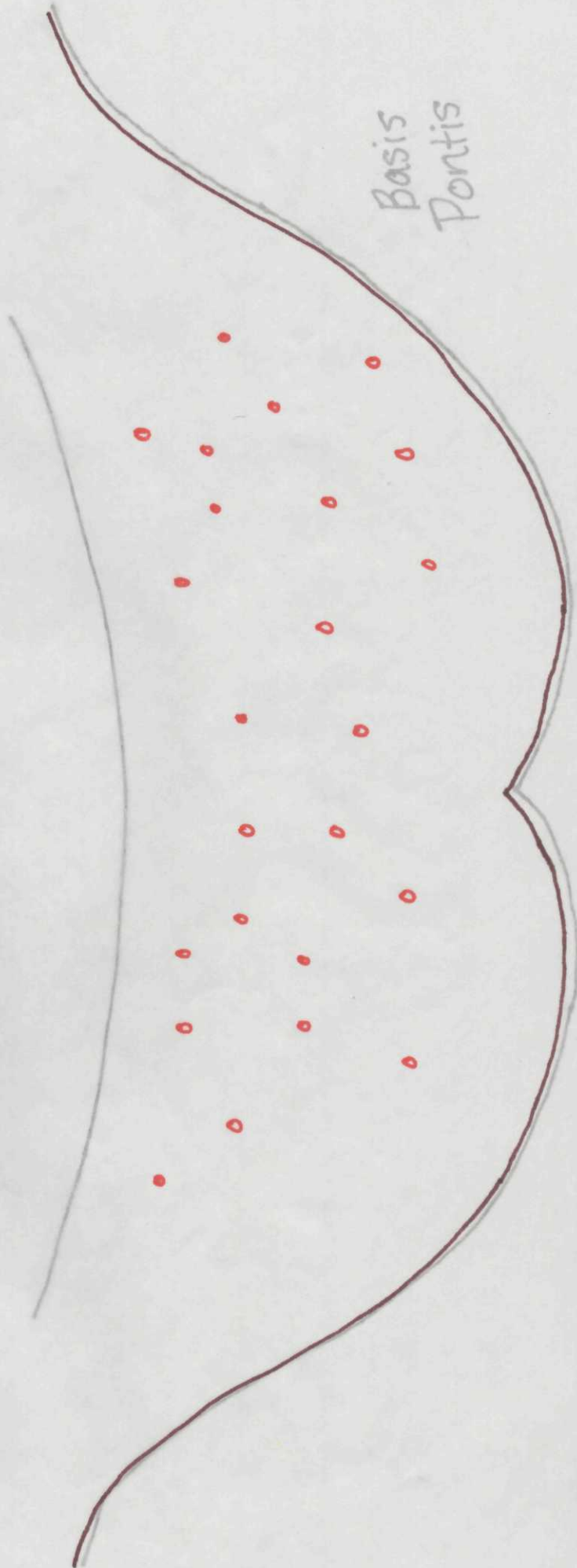
Other Nuclei
Pontine Nuclei
Reticular f.

Superior
Cerebellar
Peduncle

Middle
Cerebellar
Peduncle

Basis
Pontis

#



PONS

4th

White Matter Tracts
Medial Lemniscus
CTF



Ant Spino cereb.

Spinothalamic

Rubrospinal

CS, CP


Pontocerebellar



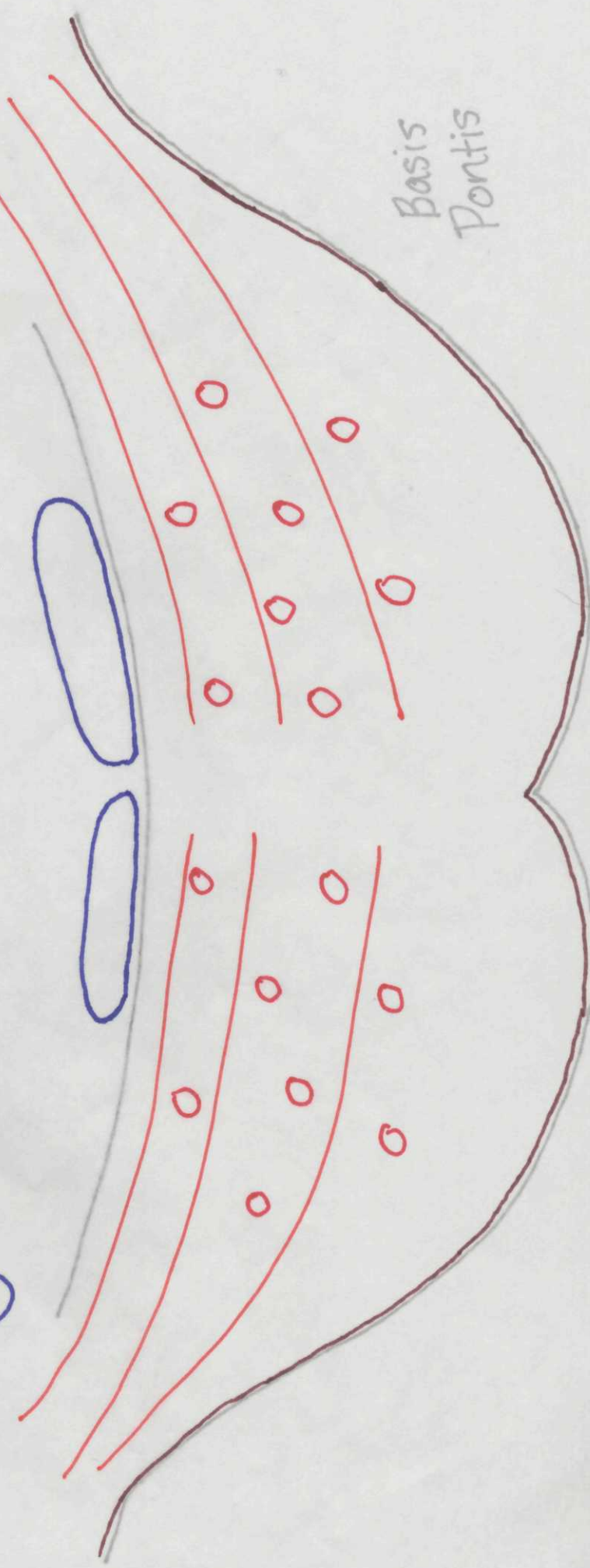
Superior
Cerebellar
Peduncle



Middle
Cerebellar
Peduncle



Basis
Pontis



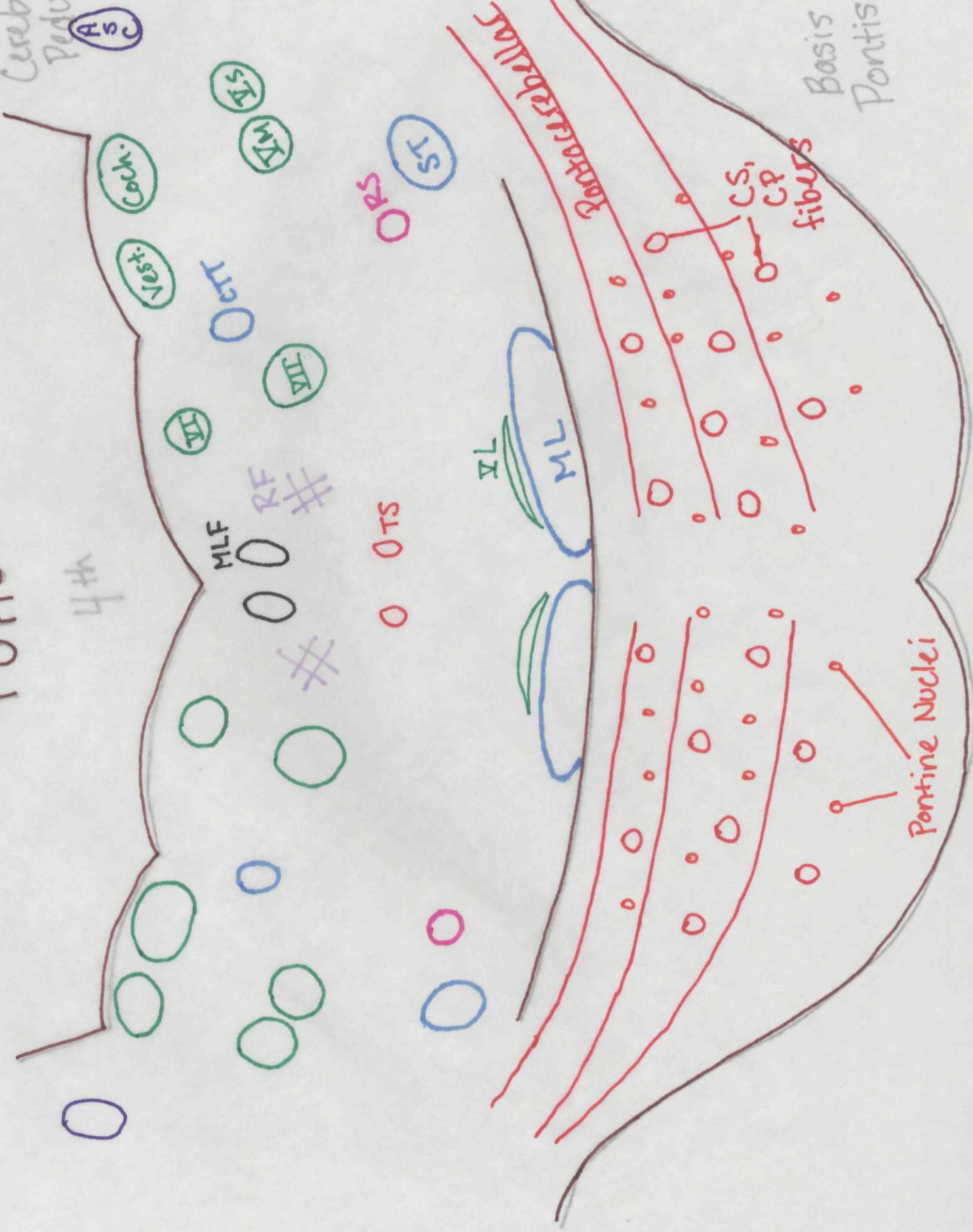PONS

4th

Superior
Cerebellar
Peduncle

Middle
Cerebellar
Peduncle

Basis
Pontis



PONS

4th

Superior
Cerebellar
Peduncle

Middle
Cerebellar
Peduncle

Basis
Pontis

