

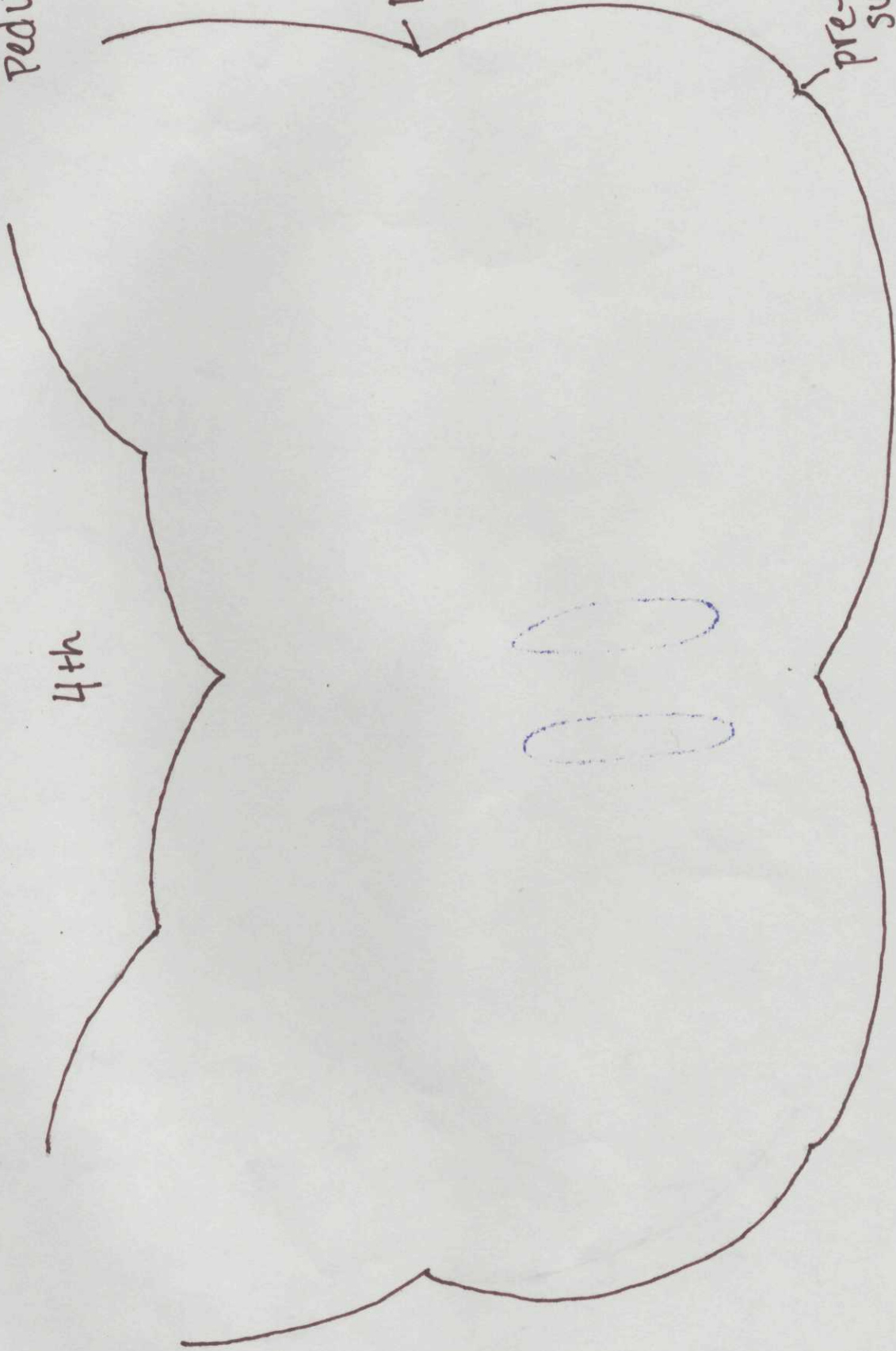
Upper Medulla

Inferior cerebellar Peduncle

4th

post-olivary sulcus

pre-olivary sulcus



Upper Medulla

CNN

Spinal Nucleus of V

MLF

Vestibular

Solitary

Motor of Vagus

Hypoglossal

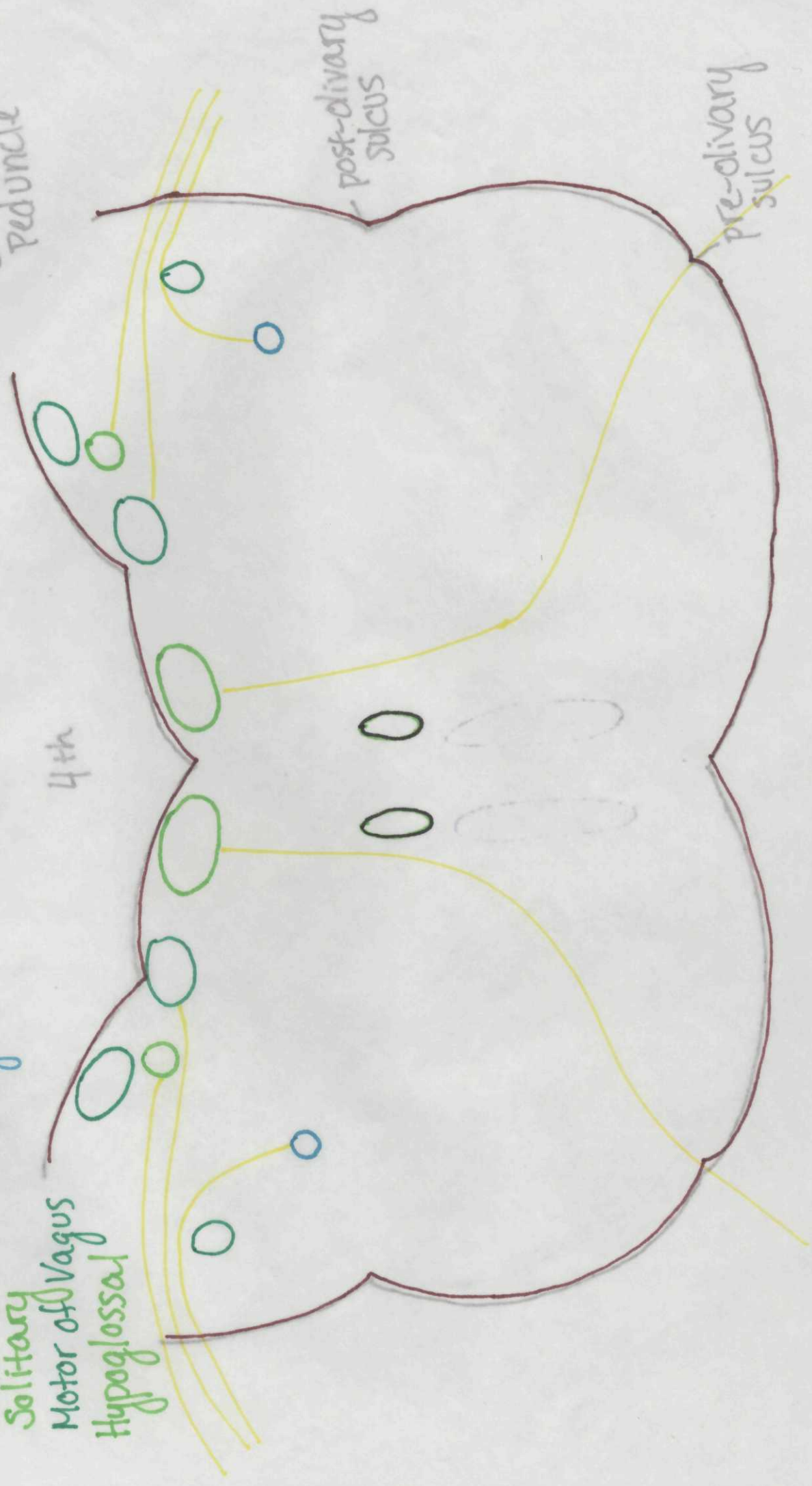Ambiguous

4th

Inferior cerebellar Peduncle

post-divary sulcus

pre-divary sulcus



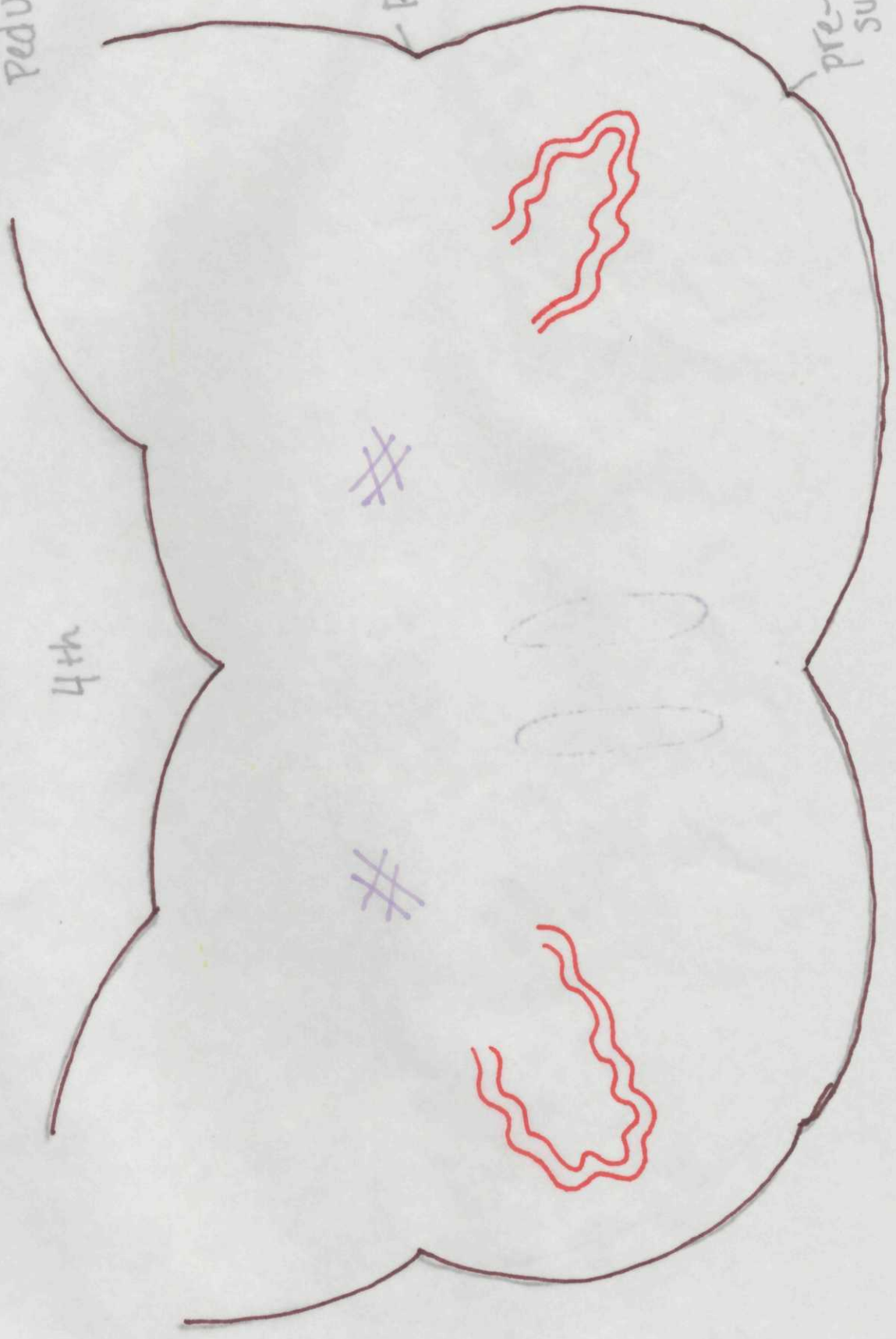Upper Medulla

Other Nuclei
Inferior Olivary N.
Reticular F.

Inferior
Cerebellar
Peduncle

post-olivary
sulcus

pre-olivary
sulcus



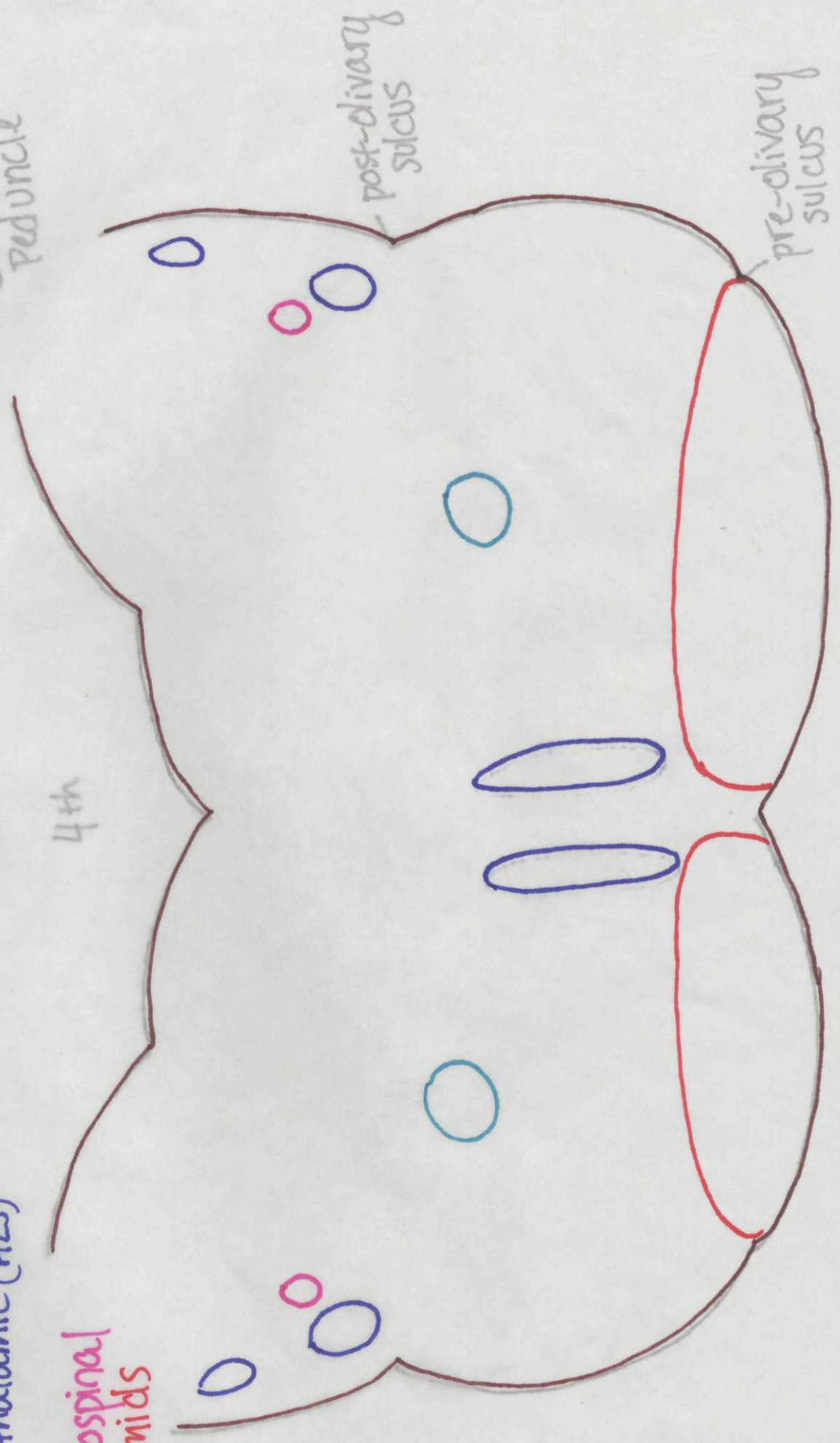
Upper Medulla

- White Matter Tracts
- Medial Lemniscus
- Ant Spino cereb.
- Spinothalamic (ALS)
- CTT
- Rubrospinal Pyramids

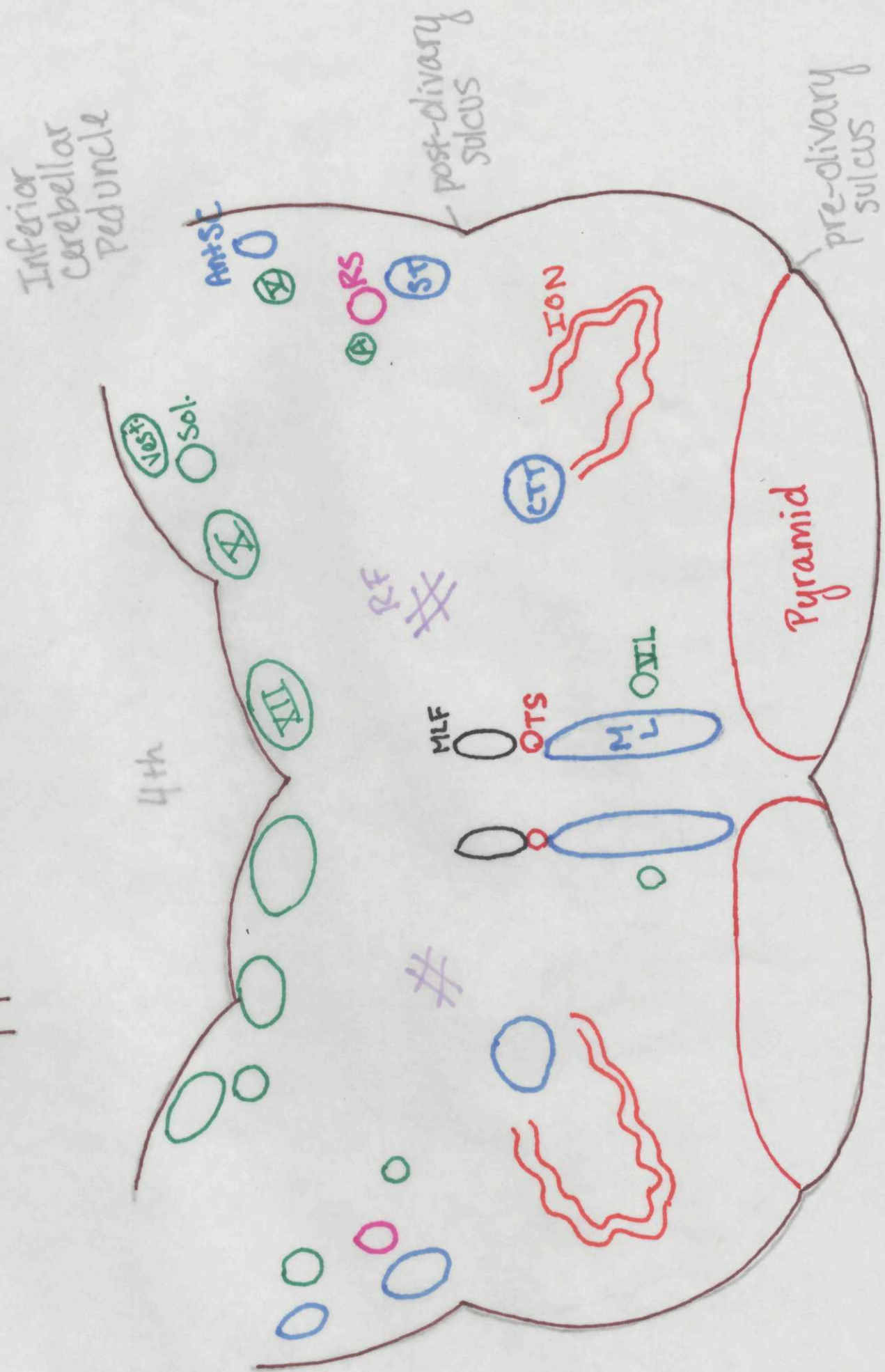
Inferior cerebellar Peduncle

post-divary sulcus

pre-divary sulcus



Upper Medulla



Upper Medulla

