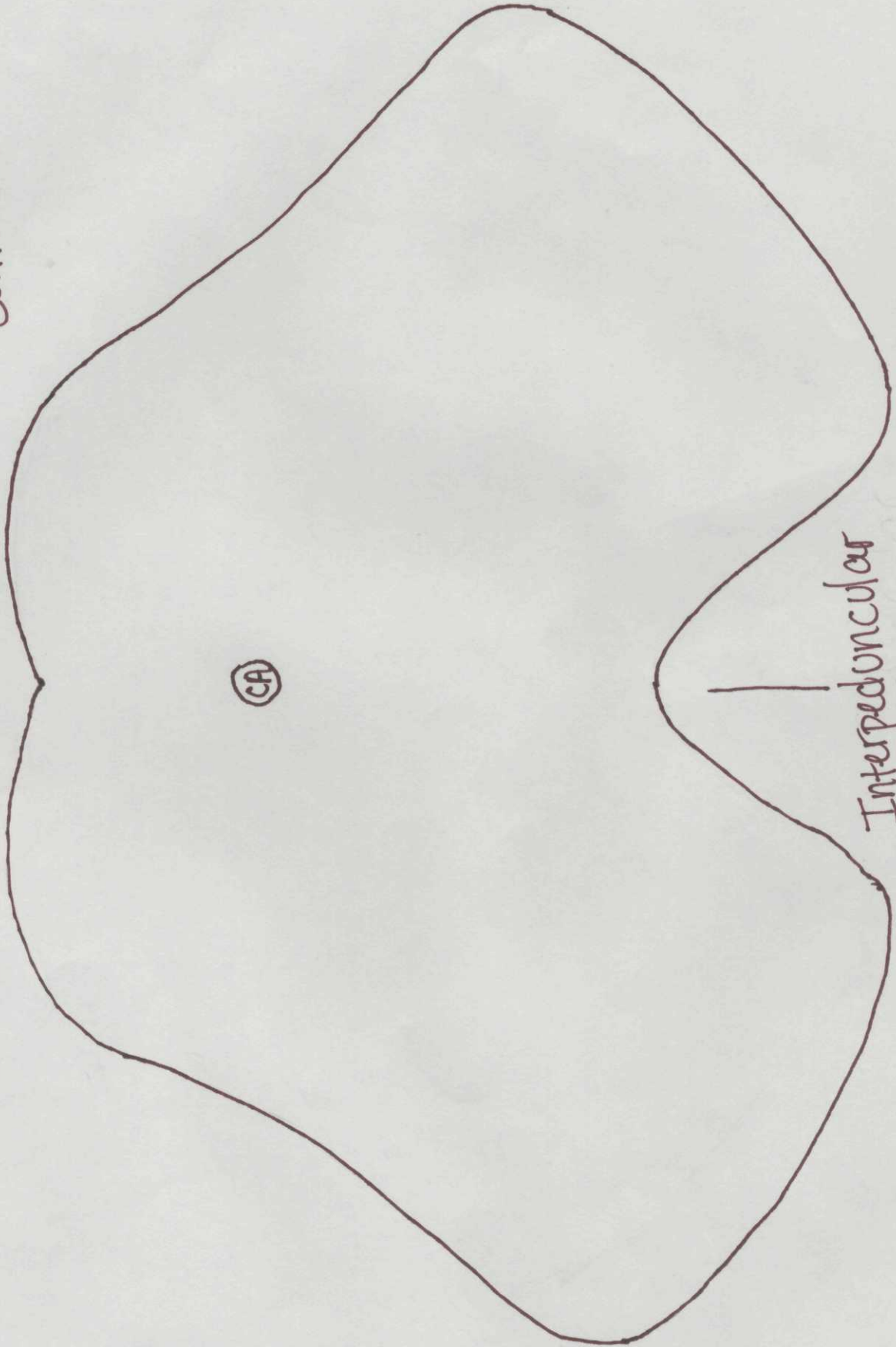


Upper Midbrain

Superior Colliculus

CA

Interpeduncular Fossa



Upper Midbrain

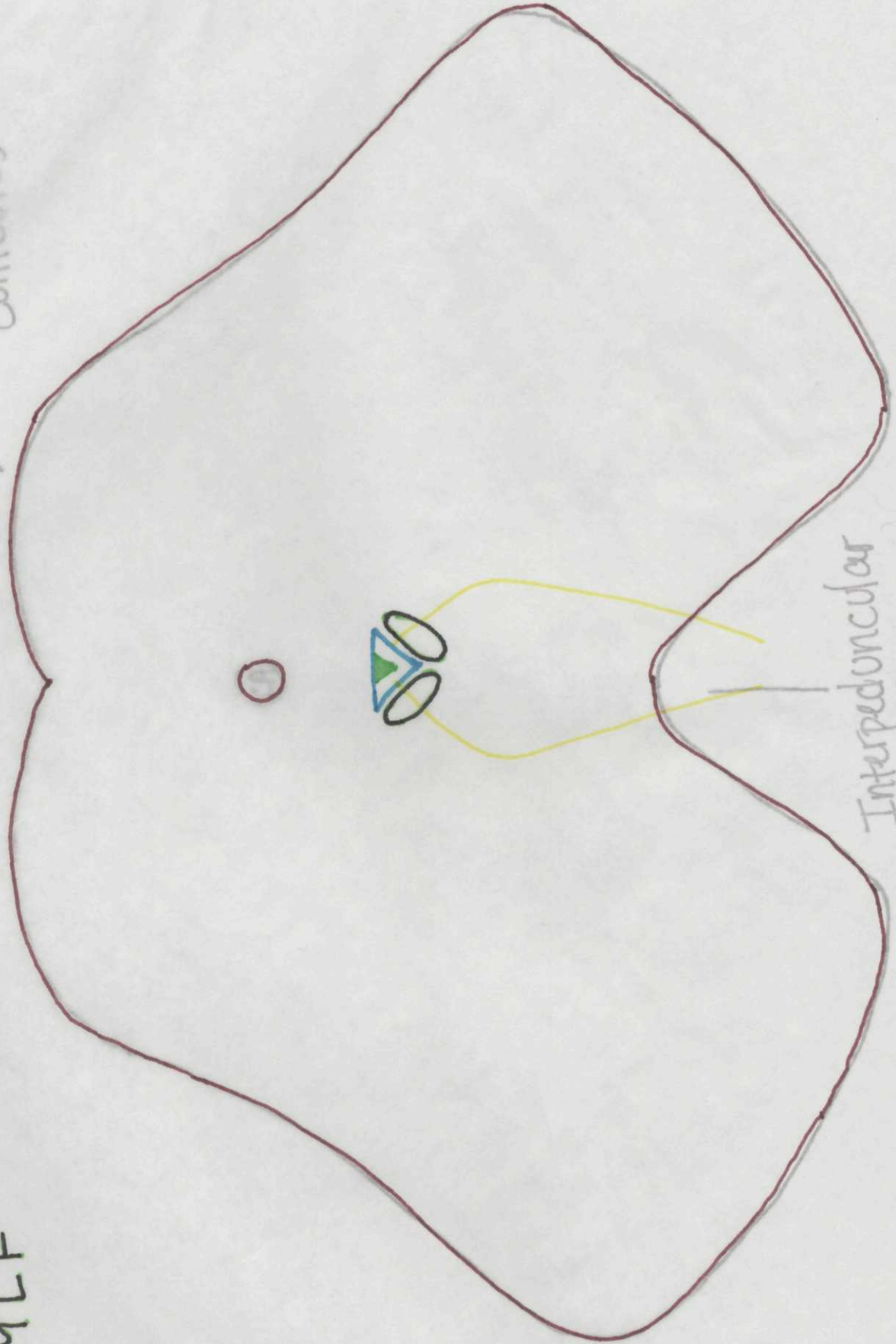
CNN

Edinger-Westphal N.

Oculomotor

MLF

Superior Colliculus



Upper Midbrain

Other Nuclei

Periaqueductal Gray
Superior Colliculus

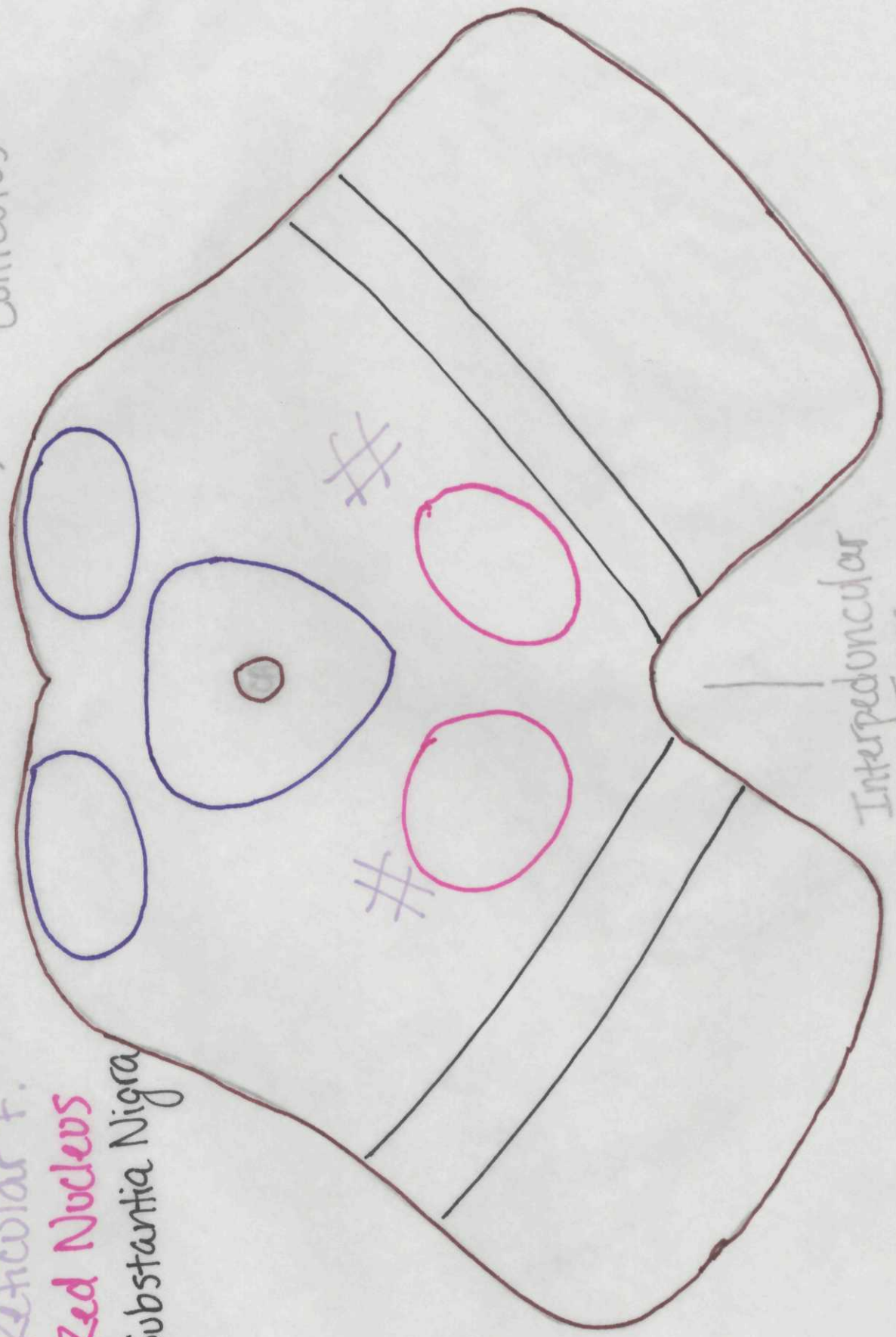
Reticular F.

Red Nucleus

Substantia Nigra

Superior Colliculus


Interpeduncular Fossa



Upper Midbrain

- White Matter Tracts
- Cerebral Peduncle
- Medial Lemniscus
- Spinothalamic T.
- CTT

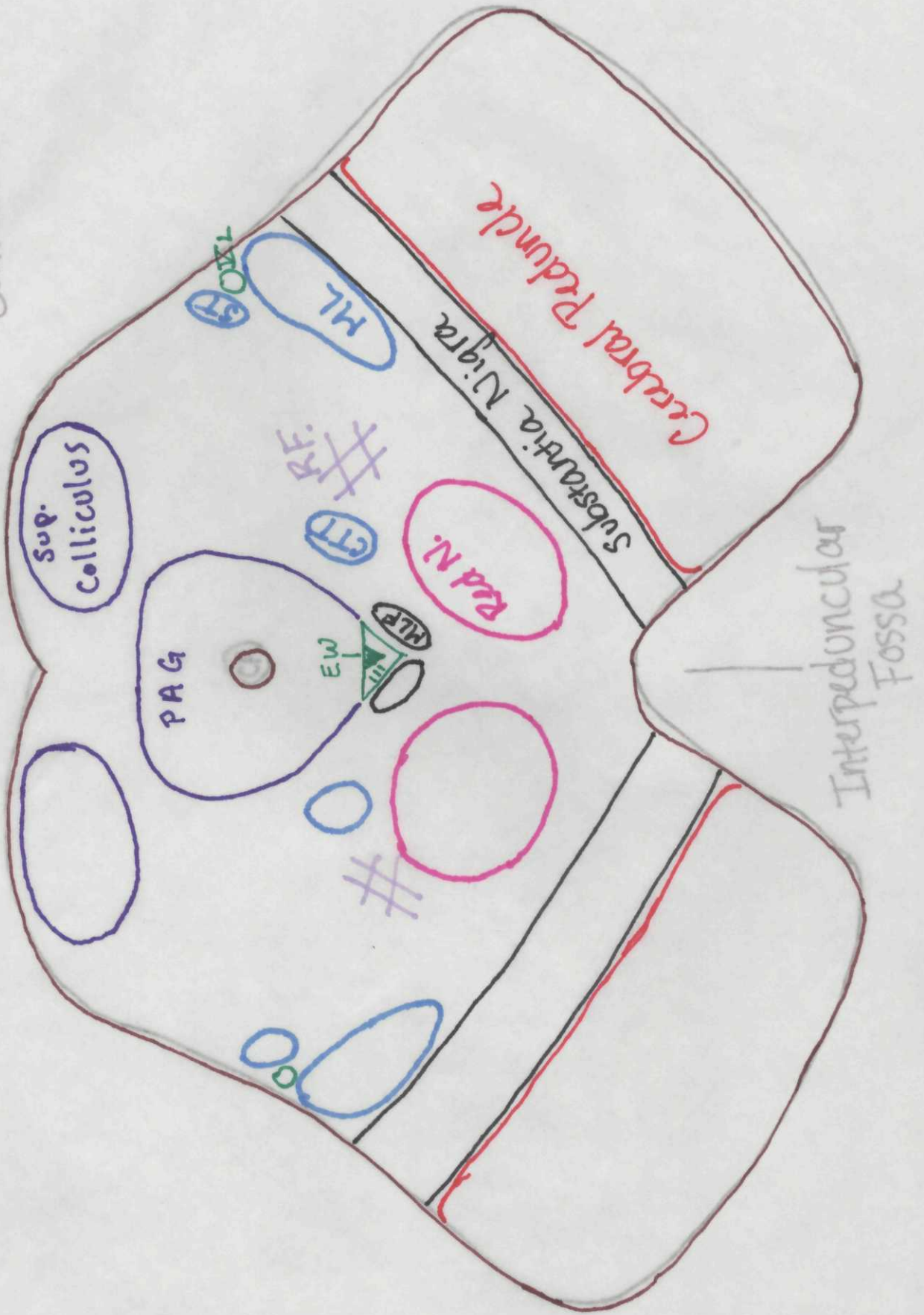
Superior Colliculus



Interpeduncular Fossa

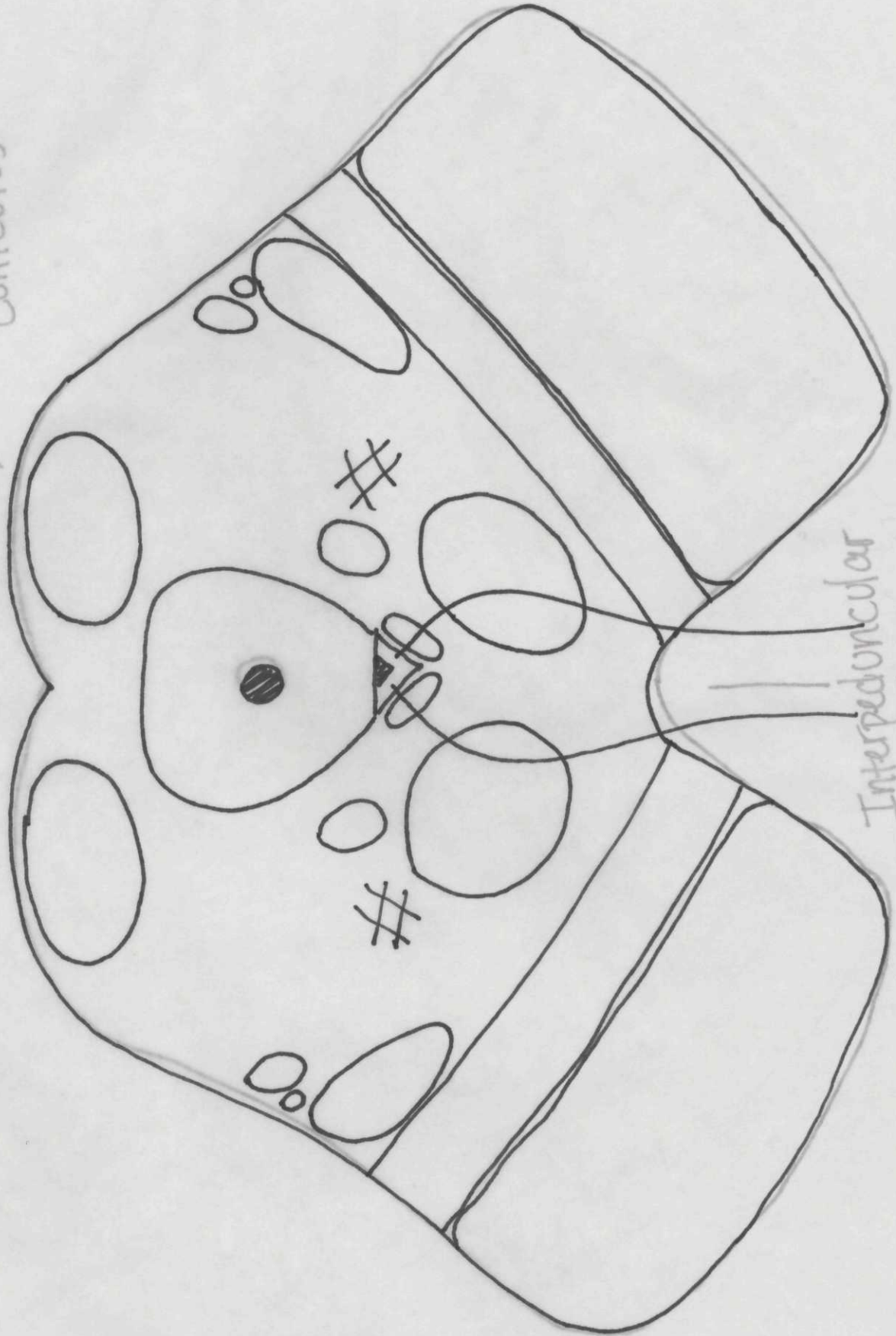
Upper Midbrain

Superior Colliculus



Upper Midbrain

Superior Colliculus



Interpeduncular Fossa